

March 30, 2023

JONATHAN HAMRICK, M.D.
COALINGA STATE HOSP.
COALINGA CA

In Reference to : Jeffrey Gambord
ID No: 400509
DOB : 11/05/1960 AGE : 62
SEX : Male
Exam Date : 03-30-2023

Dear Dr. HAMRICK,

Thank you for referring Jeffrey Gambord. I performed an upper Endoscopy on Jeffrey Gambord. Please find the enclosed reports which show my findings, impressions and recommendations.

Indications

Cirrhosis of liver, unspecified
Esophageal varices without bleeding
History of gastric ulcer
Obesity, unspecified

Impressions

Esophagitis, unspecified
Esophageal varices without bleeding
Other gastritis without bleeding
Portal gastropathy seen

Plan


Continue same meds.

Avoid: citrus juices, cigarettes, chocolate, tight fitting clothing, coffee and other caffeinated beverages, carbonated beverages, fatty and fried foods, anticholinergic medications, medications which decrease LES tone (Ca channel blockers, theophyline preparations).

EGD after 6 months for F/U of Esophageal Varices.

Loose wt.

Truly yours,



Prahalad B. Jajodia, M.D.

CONFIDENTIAL
INDIVIDUAL'S COPY

DISCHARGE INSTRUCTIONS FOR ESOPHAGOGASTRODUODENOSCOPY

PATIENT ID/MRN : 400509 DOB: 11/5/1960 Date: 03/30/2023
PATIENT NAME : Jeffrey Gambord
PATIENT ADDRESS: COALINGA STATE HOSPITAL COALINGA CA 93210

RESTRICTION ON ACTIVITY

1. Do not drive or operate machinery until the day after the procedure.
2. Following day - Return to usual activity, unless otherwise instructed.
3. Diet - Avoid alcohol for 24 hours after procedure; otherwise eat and drink as usual.

TREATMENT FOR COMMON AFTER EFFECTS

1. Sore Throat - Treat with throat lozenges; gargle with warm salt water.
2. Mild abdominal pain and bloating - Rest and take liquids only.

SYMPTOMS TO WATCH FOR AND REPORT TO YOUR PHYSICIAN

1. Chills or fever occurring within 24 hours after procedure.
2. Pain in chest.
3. Severe abdominal pain or bloating.
4. Severe or persistent pain, nausea or vomiting.
5. Signs of bleeding.
6. I.V. site swelling / redness.

IF BIOPSY HAS BEEN TAKEN

1. Consult your physician before taking any medications.
2. If GI bleeding occurs, call your physician.
3. Limit travel.

IMPRESSIONS :

Esophagitis, unspecified
Esophageal varices without bleeding
Other gastritis without bleeding
Portal gastropathy seen

SPECIAL INSTRUCTIONS:

Continue same meds.

Avoid: citrus juices, cigarettes, chocolate, tight fitting clothing, coffee and other caffeinated beverages, carbonated beverages, fatty and fried foods, anticholinergic medications, medications which decrease LES tone (Ca channel blockers, theophyline perparations).

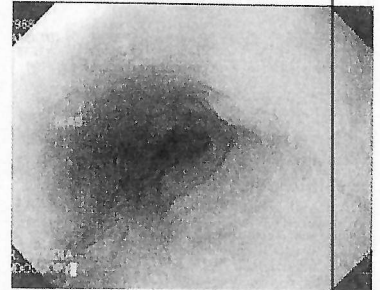
EGD after 6 months for F/U of Esophageal Varices.

Loose wt.

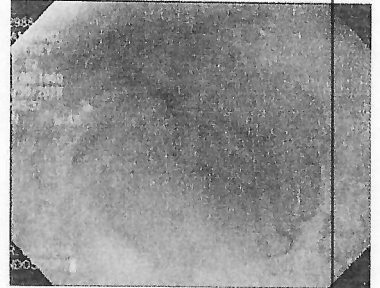
Signature: P. B. Jajodia, MD 'Date: 3/30/2023 12:49:50 PM'
Prahald B. Jajodia, M.D.

Signature (Patient/Responsible Party): Jeffrey Gambord

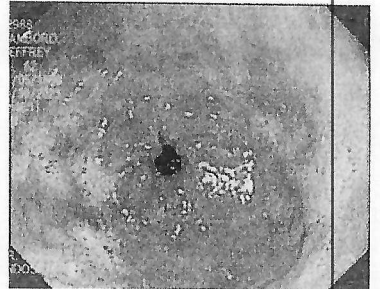a. Esophageal varices Grade B



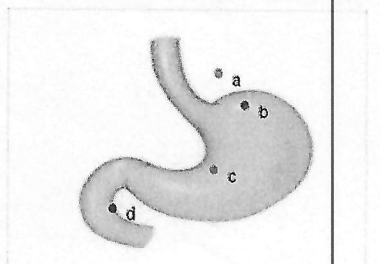
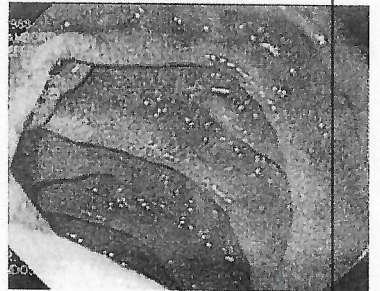
b. Hiatal Hernia.



c. Gastritis



d. Normal duodenum



CONFIDENTIAL

INDIVIDUAL'S COPY

ESOPHAGOGASTRODUODENOSCOPY REPORT

PATIENT NAME	PATIENT ID	DOB	AGE	SEX	EXAM DATE	ATTENDING PHY	REFERRAL
Jeffrey Gambord	400509	11/5/1960	62	M	03-30-2023	Prahalad B. Jajodia, M.D.	JONATHAN HAMR M.D.

ASST/NURSE : Karen Philp, CRNA Aman, RN Margarita Hernandez, GI Tech
Gary Schellenberg, GI Tech Marina Hayhurst, Surgical Tech

INDICATION : Cirrhosis of liver, unspecified - K74.60
Esophageal varices without bleeding - I85.00
History of gastric ulcer
Obesity, unspecified - E66.9

CONSENT : Informed consent was obtained from the patient after providing any opportunity for questions.

PREPARATION : EKG pulse, blood pressure and oxygen saturation monitored.

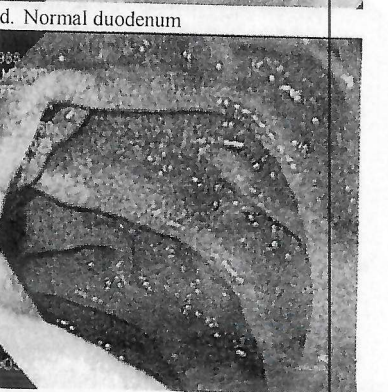
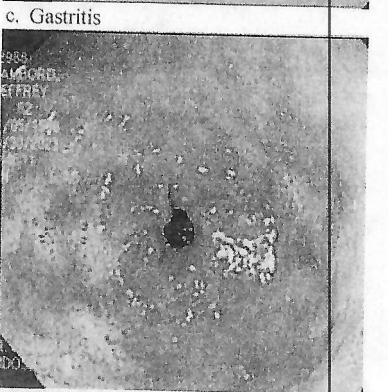
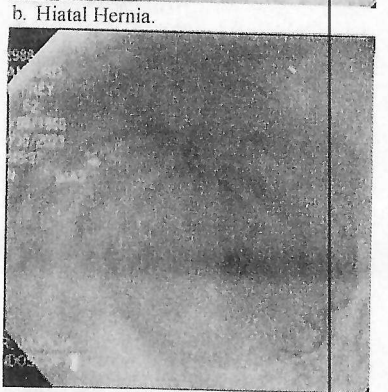
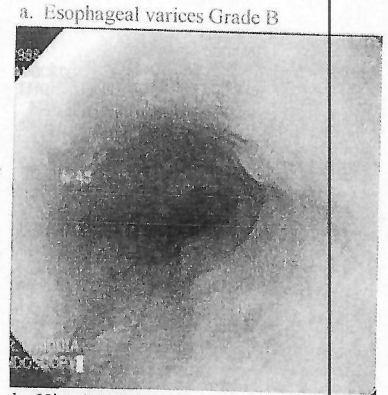
INSTRUMENT : OLYMPUS 2706019

ANESTHESIA : As Per Anesthesia

PROCEDURE : The Gastroscope was gently passed through the incisoral orifice into the oral cavity and under direct visualization the esophagus was intubated. The endoscope was passed down the esophagus, through the stomach and into the 2nd Portion. Color, texture, mucosa and anatomy of Esophagus, Stomach and Duodenum were carefully examined with the scope. The patient tolerated the procedure well and there were no complications. After completion of the examination, patient was transferred to the recovery room.

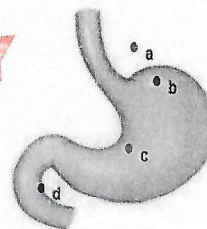
FINDINGS

- Oropharynx - Normal
- Esophagus - Mild esophagitis
Esophageal varices without bleeding
- EG-Junction - Normal
- Cardia - Normal
- Fundus - Normal
- Body - Moderate Portal hypertensive gastropathy
- Antrum - Mild gastritis
No ulcer seen.
- Pylorus - Normal
- Duodenum Bulb - Normal
- 2nd Portion - Normal



*Win...
Oivi...
CONFIDENTIAL
INDIVIDUAL'S COPY*

JUL 06 2023



Patient Name: mbord

Patient ID: 4005

Exam 03-30-2023

IMPRESSION

: Esophagitis, unspecified - K20.9
Esophageal varices without bleeding - I85.00
Other gastritis without bleeding - K29.60
Portal gastropathy seen

PLAN

: Continue same meds.

Avoid: citrus juices, cigarettes, chocolate, tight fitting clothing,
coffee and other caffeinated beverages, carbonated beverages
, fatty and fried foods, anticholinergic medications, medications
which decrease LES tone (Ca channel blockers, theophylline
preparations).

EGD after 6 months for F/U of Esophageal Varices.

Loose wt.

CPT CODES

: 43235 - EGD, flexible, transoral; diagnostic
44360 - Endoscopy small bowel (separate procedure)

This report has been reviewed by attending physician

Electronic Signature:

Prahalad B. Jajodia, MD

Date: 3/30/2023 12:49:52 PM

Prahalad B. Jajodia, M.D.

CONFIDENTIAL
INDIVIDUAL'S COPY

*Wish Staff
Wish Staff*

JUL 06 2023